

# GYNAECOLOGY & OBSTETRICS UPDATE

Issue 48

April, 2006

Author

**T.M. Malak**

MB, BCh., M.Sc.,  
Ph.D., DFFP,  
MRCOG, FRCOG

Consultant  
Obstetrician  
Gynaecologist &  
Urogynaecologist


Tel: 01323 414816/  
410717/ 410929  
Fax: 01323 730313

Web address  
For Professionals  
MarkMalak.com

For Patients  
MrMalak.com  
Finalist

**HOSPITAL  
DOCTOR**

**AWARD  
2005**



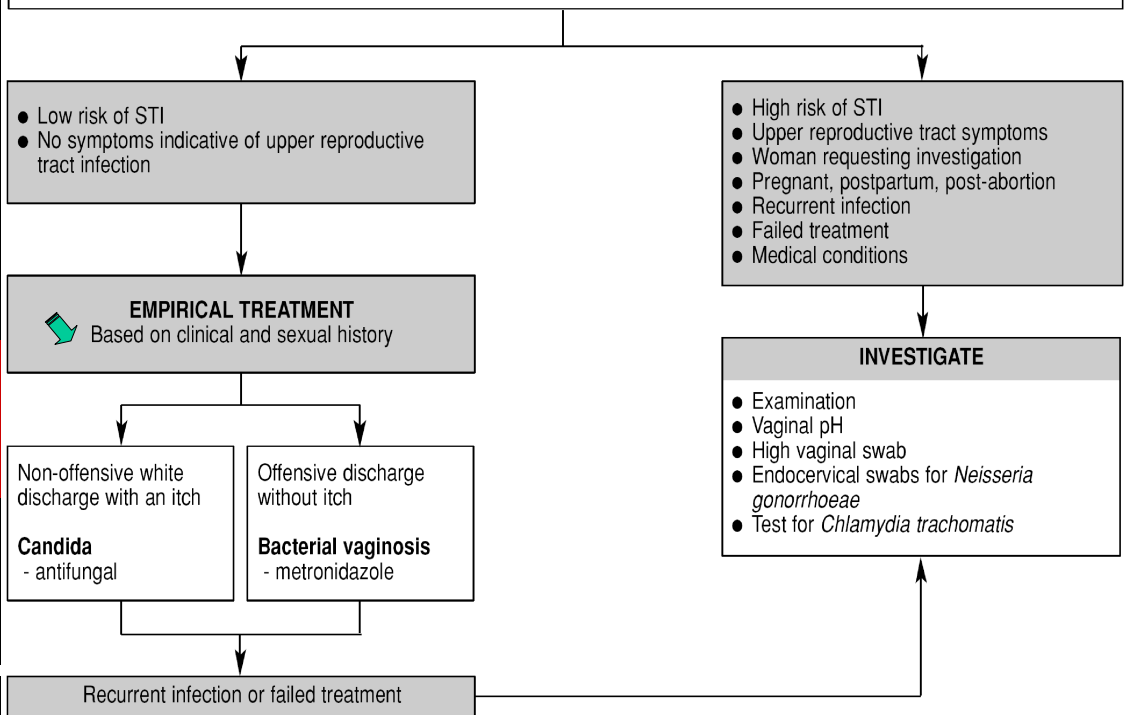
I wish you a very  
**Happy  
Easter**

## Vaginal Discharge The management of women of reproductive age

In women of reproductive age complaining of vaginal discharge the commonest cause is physiological, but infective and other causes (e.g. foreign body, cervical ectopy) should be excluded. vaginal discharge.

### CLINICAL AND SEXUAL HISTORY

- Why is she presenting now? What are her concerns?
- Characteristics of the discharge (what has changed, odour, onset, duration, colour, consistency)
- Associated symptoms (itch, superficial dyspareunia, dysuria) and those indicative of upper reproductive tract infection (abdominal pain, STIs, deep dyspareunia, abnormal bleeding, dysuria, pyrexia)
- Sexual history for risk of STIs (higher if aged <25 years; new partner or more than one partner in the last year)
- Contraceptive use, pregnancy, postpartum, post-abortion
- Concurrent medications (e.g. antibiotics, corticosteroids); previous treatments used (prescription and over-the-counter)
- Medical conditions (e.g. diabetes, immunocompromised state)
- Consider non-infective causes of discharge (e.g. foreign body, cervical ectopy or polyps, genital tract malignancy)



Bacterial vaginosis	Candida	Trichomoniasis
Thin discharge	Thick white discharge	Scanty to profuse or frothy yellow discharge
Offensive or fishy odour	Non-offensive	Offensive
<i>Associated symptoms:</i> No itch	<i>Associated symptoms:</i> Vulval itch or soreness Superficial dyspareunia External dysuria	<i>Associated symptoms:</i> Vulval itch Dysuria Low abdominal pain
Discharge coating vagina and vestibule No vulval inflammation	Normal findings <i>or</i> Vulval erythema, oedema, fissuring, satellite lesions	Vulvitis and vaginitis So-called strawberry cervix (uncommon 2%)

Reference: Journal of Family Planning and Reproductive Health Care 2006; 32(1): 33-42